

RESULTS

The long-term follow up was performed six months after the operation and the final postoperative assessment was done twelve months after the operation.

We assessed our patients post-operatively on clinical and radiological basis:

Clinically ;

The patients were examined two, four, six weeks and at the time of removal of the external fixator, eight weeks post-operatively, six months after the operation and finally after one year to assess.

- 1- function of the by assessment of the range of movement. (ROM)
- 2- Any displacement of the fracture fragments as the fixator were loosened and re-reduction were performed in five patients (20% of the cases) during follow up and to assess the presence of pin track infection, which occurred in four fractures (16% of the cases) where meticulous daily care and aggressive treatment with antibiotics were performed.

Radiologically;

All patients were assessed radiologically two, four, six weeks and at the time of removal of the external fixator eight weeks post-operatively - during the rehabilitation period-to assess:

- 1- The fracture displacement which occurred in five fractures (20% of cases).
- 2- The formation of callus (healing), as it appears in the x-rays six weeks postoperatively in 21 fractures (84% of cases), and twelve weeks postoperatively there were extra two patients showed formed

Results


callus (8% of cases) and considered as delayed union, and the rest two patients (8% of cases) showed fibrous union as the injured arm moved as uniformed aligned solid limb without radiological evidence of callus formation after 16 weeks postoperatively [Table 11].

N.B. One of cases with fibrous union needed bone marrow injection in the fracture site under image intensifier control after twenty weeks of injury . Radiological evidence of healing could be obtained after further twelve weeks and the other case refused any further management .

Table (11): Clinical and radiological evaluation of union.

Union	Number of fractures	Percentage
United	21 fractures	84%
Delayed union	2 fractures	8%
Fibrous union	2 fractures	8%
Non-union	Nil	0%

Chart (11): Clinical and radiological evaluation of union



Results

We adopt the rating system of Neer to evaluate the results of transcutaneous reduction and Hoffmann external fixation of displaced fractures of the proximal humerus.

Rating (Scoring) System

Neer's rating system based on 100 units. There are 35 units for pain, 30 units for function, 25 units for range of motion, and 10 units for anatomy. Pain is the most significant factor. An excellent result is greater than 89 units; satisfactory, greater than 80 units; unsatisfactory greater than 70 units; and failure, less than 70 units. But, as the visual analogue score of pain which was created by Neer was difficult to be performed, we classified the pain scoring system into four grades.

When patient was asked to abduct his arm till 90°, as the highest grade was achieved when doing such abduction without pain.

Lower grade when it was not difficult to abduct the arm 90°.

More lower grade when it was difficult to do such abduction because of pain .

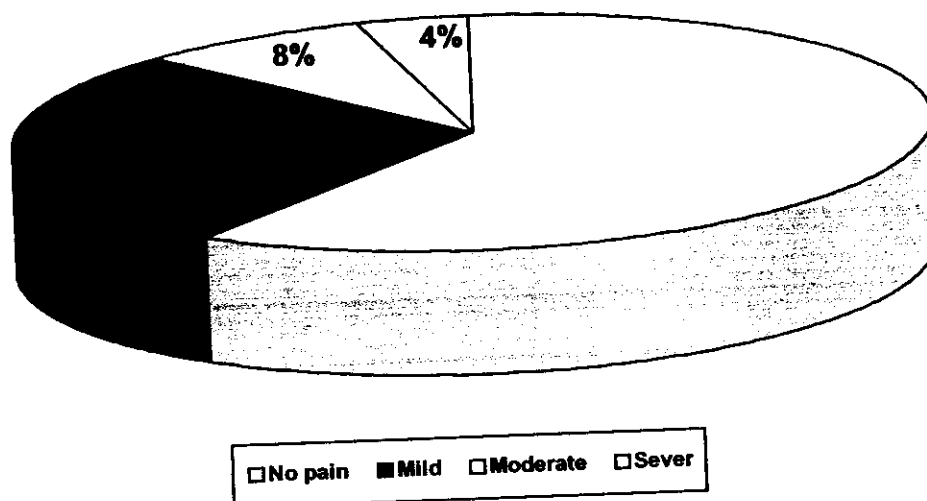
The lowest grade was achieved when the patient was unable to do it because of severe pain with abduction [Table 12].

Table (12): Clinical assessment of pain in Neer's scoring system.

Pain	Score	Number of fractures	Percentage
No pain	35	15	60%
Mild (not difficult to do)	26-34	7	28%
Moderate (difficult to do)	16-25	2	8%
Sever (unable to do)	0-15	1	4%

Results

Chart (12): Clinical assessment of pain in Neer's scoring system.



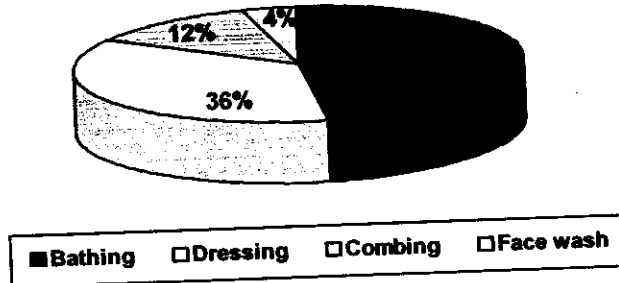
Assessment of function in our study was based on four daily activities graded according to difficulty, as the most high grade was put for bathing, lower grade was put for dressing, more lower grade was put for combing and finally the lowest grade was put for face washing [Table 13].

Table (13): Clinical assessment of function in Neer's Scoring system

Function	Score	Number of fractures	Percentage
Bathing	30	12	48%
Dressing	20-29	9	36%
Combing	11-19	3	12%
Face wash	1-10	1	4%

Results

Chart (13): Clinical assessment of function in Neer's Scoring system

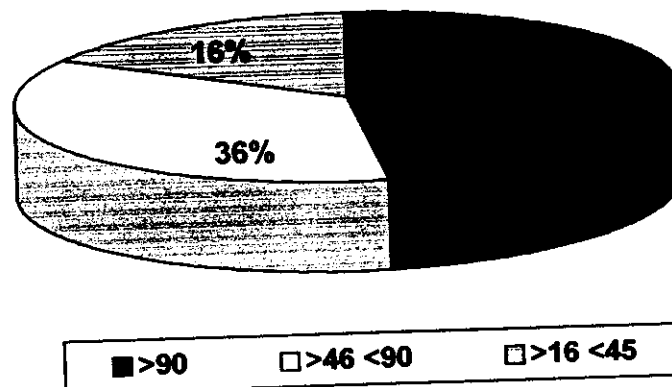


Assessment of range of motion in our study was graded in four grades according to the ability of the patient to abduct his arm from 15° to more than 90° and till 160° [Table 14]

Table (14): Clinical assessment of range of motion in Neer's scoring system

Range of abduction	Score	Number of fractures	Percentage
> 90° till 160°	25	12	48%
> 46° < 90°	16-24	9	36%
> 16° < 45°	6-16	4	16%
> 0° < 15°	0-5	0	0%

Chart (14): Clinical assessment of range of motion in Neer's scoring system



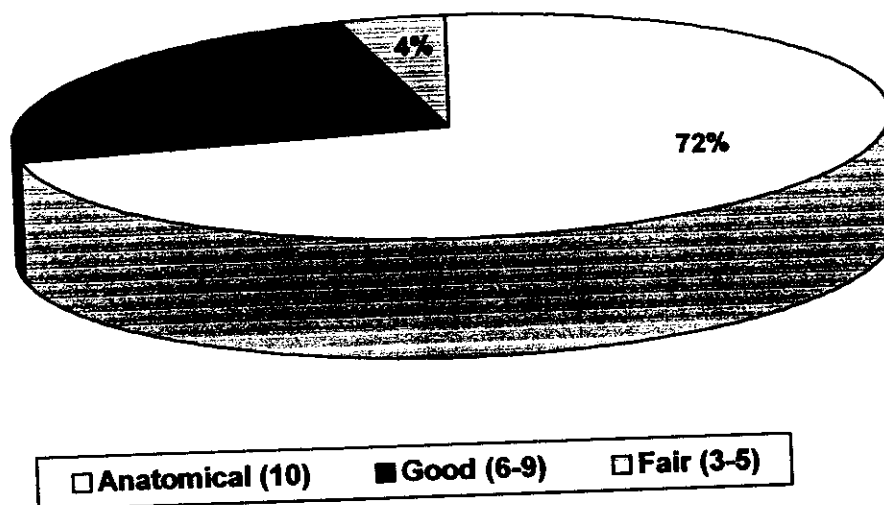
Results

Anatomical reduction was performed in 18 fractures (72 % of cases) and good reduction was achieved in 6 fractures (24% of cases) with solid bony contact, and fair reduction was approved in one fracture (4% of cases) to prevent over manipulation in a case of four- part fracture to guard against avascular necrosis of humeral head [Table 15].

Table (15): Assessment of reduction in Neer's scoring system

Reduction	Score	Number of fractures	Percentage
Anatomical	10	18	72%
Good	6-9	6	24%
Fair	3-5	1	4%
Poor	0-2	0	0%

Chart (15): Assessment of reduction in Neer's scoring system.



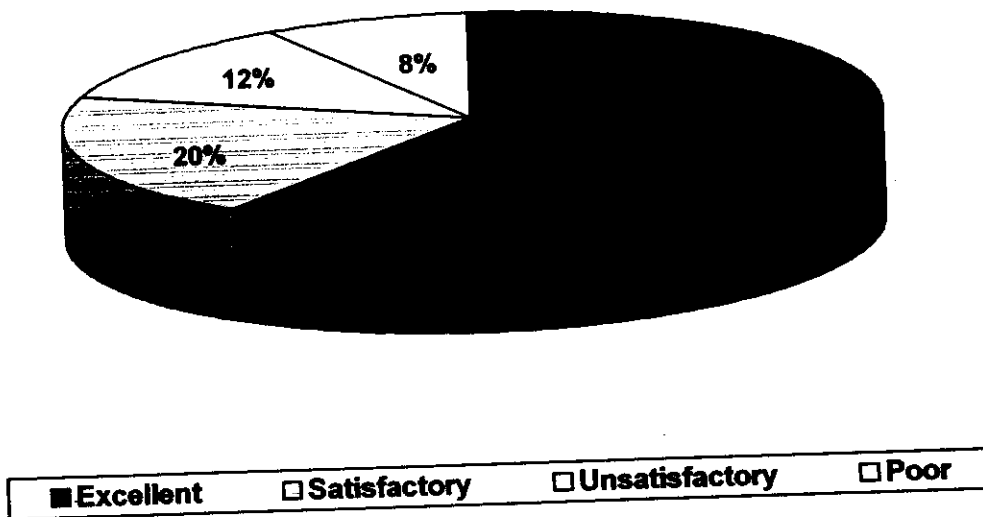
Results

The overall results in our study according to rating system of Neer were 15 (60 % of cases) excellent, 5 (20 % of cases) satisfactory, and unsatisfactory results were obtained in 3 (12 % of cases) where as there were 2 (8% of cases) poor results in our study [Table 16].

Table (16): Results according to rating system of Neer

Results	Score	Number of fractures	Percentage
Excellent	89-100	15	60%
Satisfactory	80-88	5	20%
Unsatisfactory	70-79	3	12%
Poor	0-70	2	8%

Chart (16): Results according to rating system of Neer



Results

Results in Different Age Groups:

The all four patients of age group between 14 years and 20 years showed excellent results.

Seven shoulders of eleven ones of age group between 21 years and 45 years showed excellent results. Four shoulders of ten ones of age group between 46 years and 74 years showed excellent results.

Satisfactory results were obtained in three shoulders of age group between 21 years and 45 years, and in two shoulders of the age group between 46 years and 74 years.

Unsatisfactory results were obtained in one patient of the age group between 21 years and 46 years and in two patients of the age group between 46 years and 74 years.

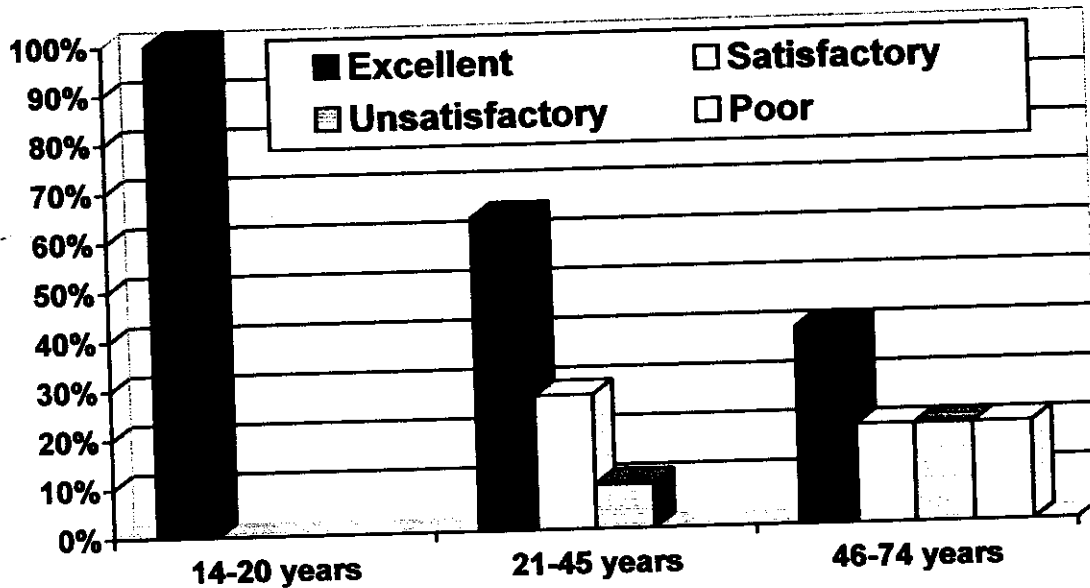
Poor results were obtained in two patients of the age group between 46 years and 74 years [Table 17].

Table (17): Results in different age groups and percentage

	Number of cases in different age groups		
	14-20 years	21-45 years	46-74 years
Results			
• Excellent	4	7	4
• Satisfactory		3	2
• Unsatisfactory		1	2
• Poor			2
Percentage			
• Excellent	100%	63.7%	40%
• Satisfactory		27.3%	20%
• Unsatisfactory		9%	20%
• Poor			

Results

Chart (17): Results in different age groups and percentage.



Results In Different Fracture Types:

Five fractures of the 6 fractures of the two-part fracture type showed excellent results whereas one fracture of such type showed satisfactory result.

Seven fractures of the 13 fractures of three-part fracture type showed excellent results. Three fractures of the 13 fractures showed satisfactory outcome and three of the 13 fractures showed unsatisfactory results.

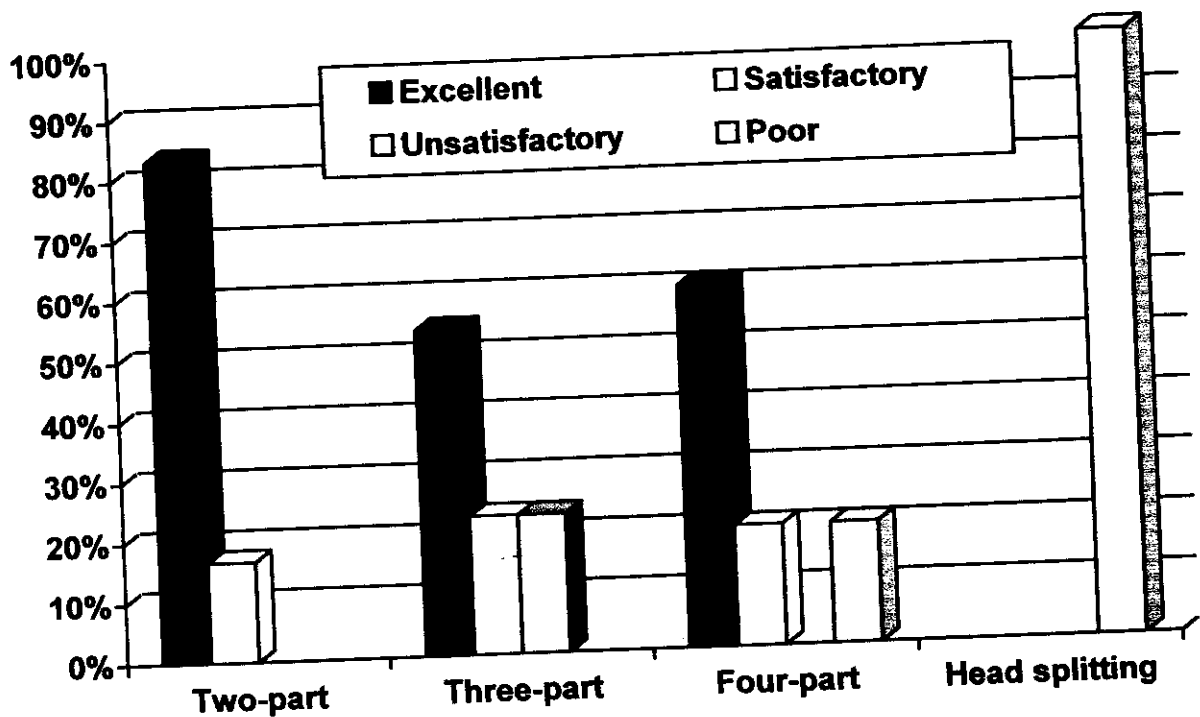
Three fractures of 5 fractures of the four-part fracture type showed excellent results. One fracture of these 5 fractures showed satisfactory outcome and one fracture showed poor result [Table 18].

Results

Table (18): Results in different fracture types and percentage

	Different fracture types			
	Two -part	Three-part	Four-part	Head splitting
Results <ul style="list-style-type: none"> • Excellent • Satisfactory • Unsatisfactory • Poor 	5 1	7 3 3	3 1 0 1	1
Percentage <ul style="list-style-type: none"> • Excellent • Satisfactory • Unsatisfactory • Poor 	83.3% 16.6%	54% 23% 23%	60% 20% 0 20%	100%

Chart (18): Results in different fracture types and percentage



Results

- Re-fracture of the proximal humerus was not occurred in our study after removal of the external fixator.
- No cases of neurovascular injury were seen in our study.

Table (19): Complications


Complications	No. of cases	Percentage
Infection	4	16%
• Pin track infection	0	0%
• Frank osteomyelites		
Loosening	5	20%
• Of fixator with re-reduction	4	16%
• Of pins with re-advancement		
Avascular necrosis	1	4%
	0	0
Refracturing	0	0
	0	0
Neurovascular injury		




X_W

(Fig.38 Avascular Necrosis of the Head of the Humerus)




Results



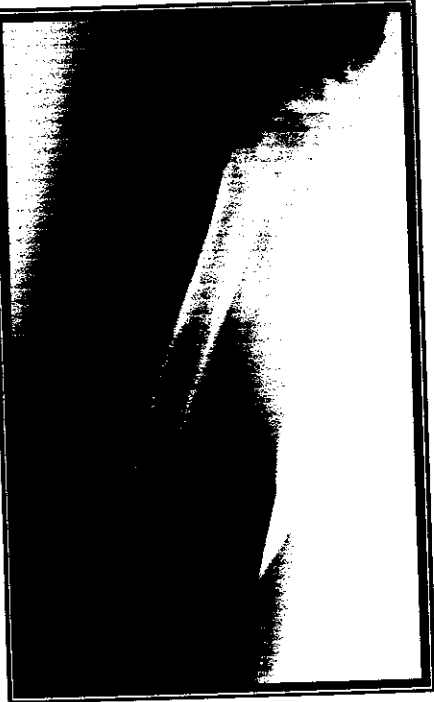



Results




Results



Results



Results



Results

Case number four :

36 years , male , manual worker , presented with right closed displaced Two-Part Proximal Humeral Fracture as a result of road traffic accident and was suffering from P.C. which was resolved after 24 hours of observation .

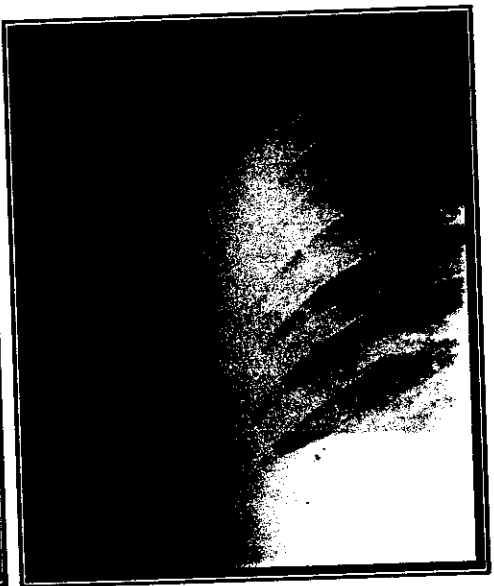
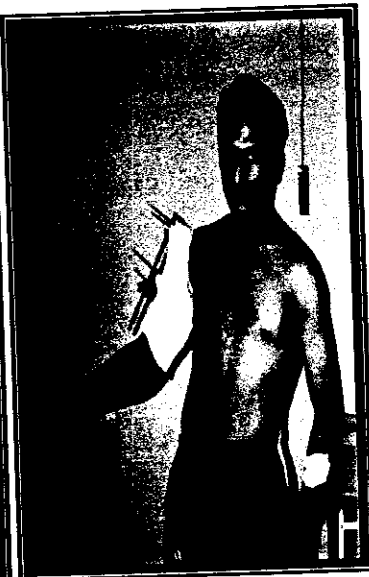
He was operated upon after 48 hours of admission as open reduction of the fracture was performed because closed reduction failed twice intra-operatively due to gathering of the biceps tendon in the fracture site , and discharged from the hospital after more 24 hours .

Post operative follow up three phase rehabilitation system was performed . During follow up period clinical and radiological assessment revealed the following last results :


- Fracture healing with radiological evidence of callus formation after 6 weeks post operatively and the fixator was removed after 8 weeks without pin track infection .

He was subjected to the Neer's rating system and showed satisfactory result with overall score 86 .

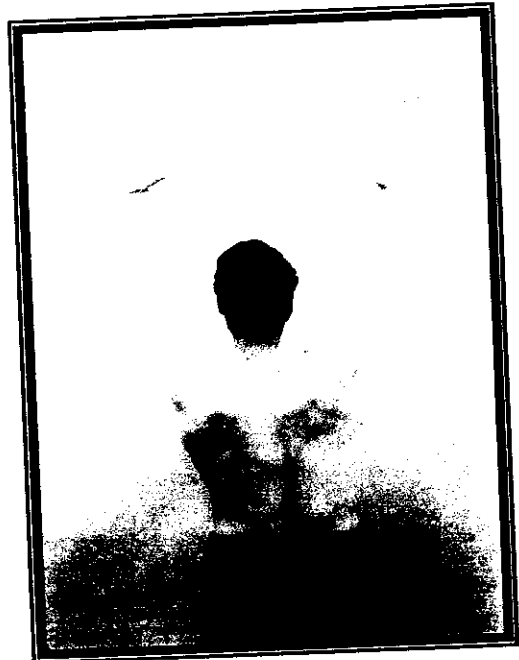
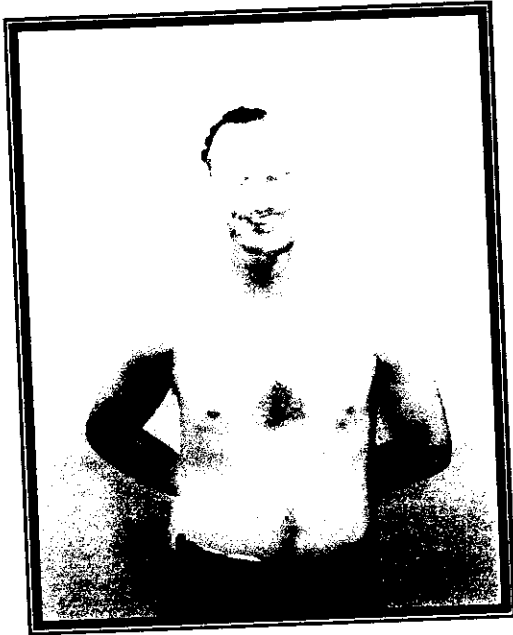

Results



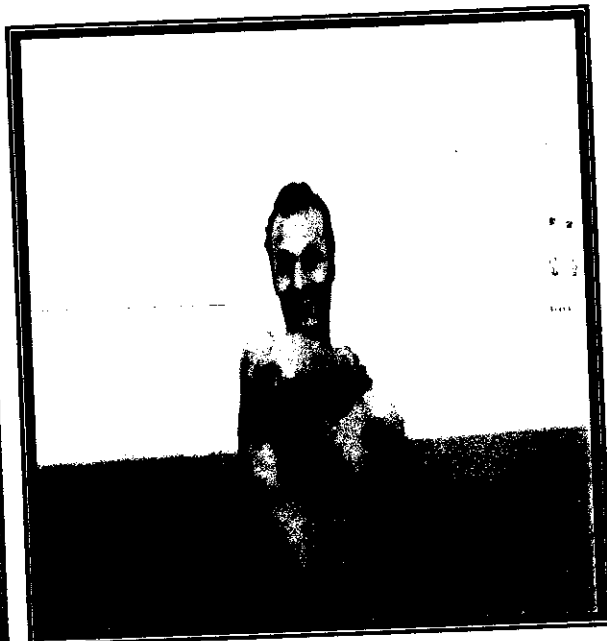
x



Results



Results



Results

Case number five :

42 years , male , clerk , presented with polytrauma as a result of road traffic accident and was suffering from P.C. which was resolved after 48 hours of observation in addition to suspicion of abdominal internal haemorrhage which was excluded by abdominal sonography . Skeletally there were bilateral closed displaced Proximal Humeral Fractures where the left one was three-part fracture and the right one was four-part fracture . Also he had had right Pylon tibial fracture .

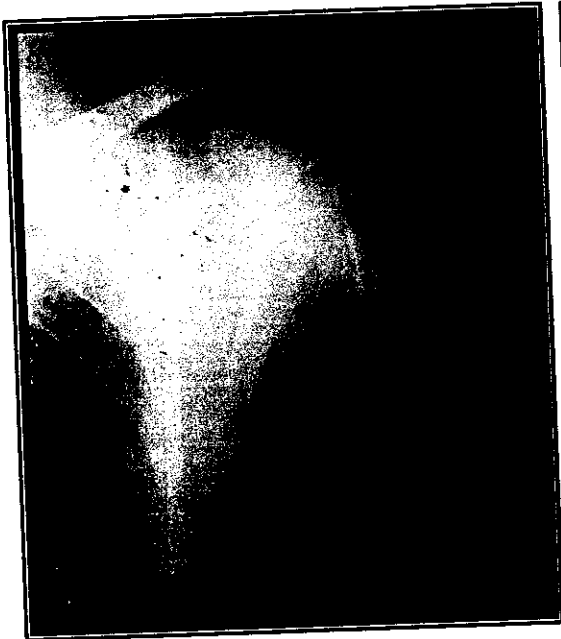
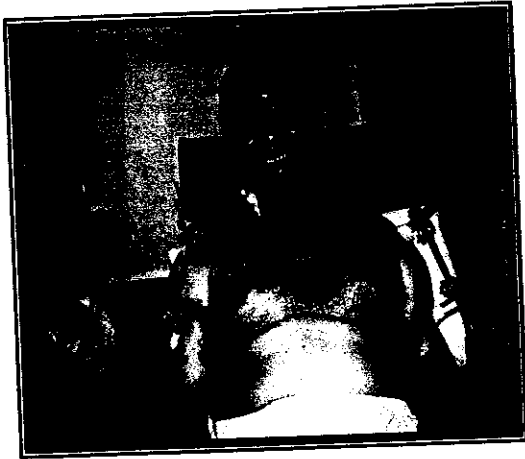
He was operated upon after one week of admission for the three skeletal injuries in the same sitting and discharged from the hospital after more one week .

Post operative follow up three phase rehabilitation system was performed . During follow up period clinical and radiological assessment revealed the following last results :

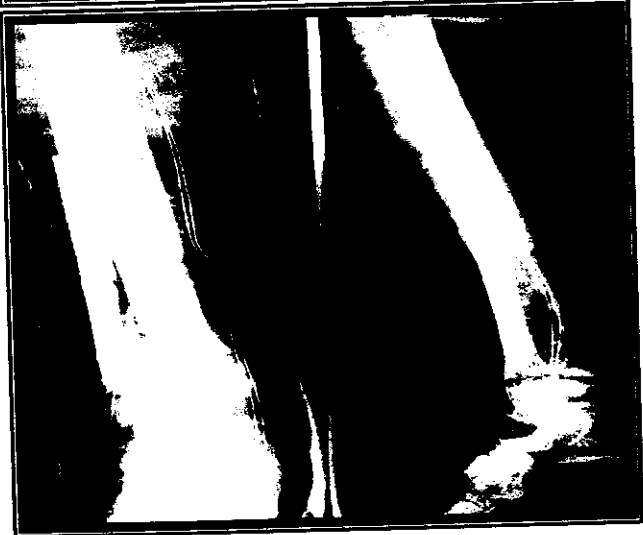
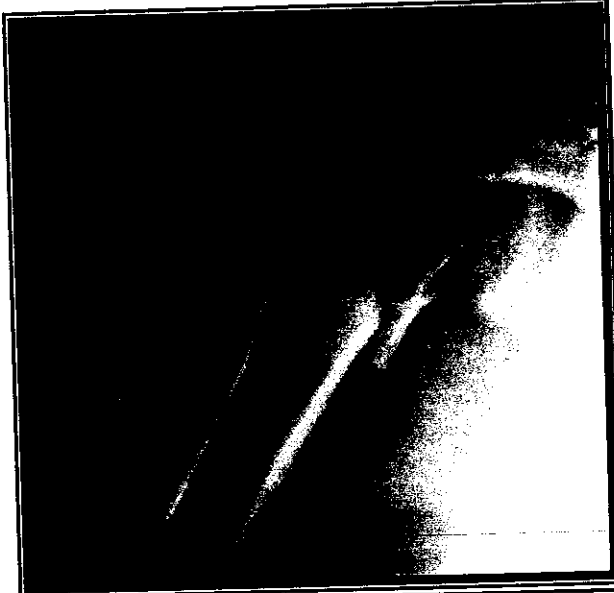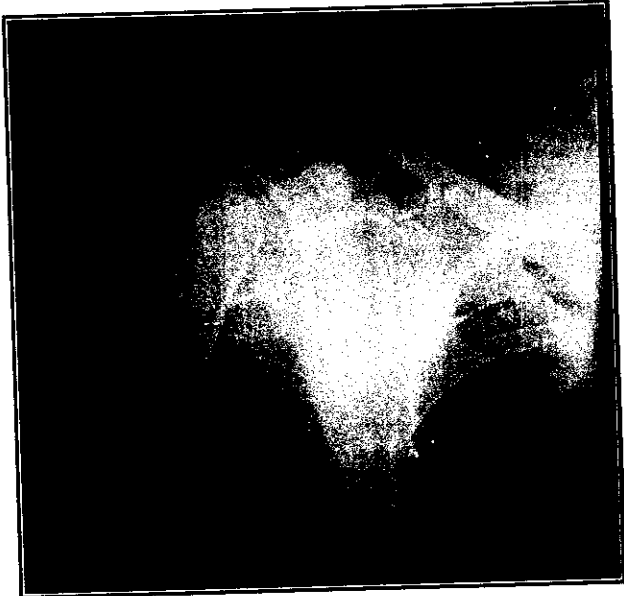- Fracture healing with radiological evidence of callus formation after 8 weeks post operatively in the left humerus and after 12 weeks in the right humerus without pin track infection .

He was subjected to the Neer's rating system and showed satisfactory result for the left shoulder with overall score 82 and unsatisfactory result for right shoulder with overall score 75.

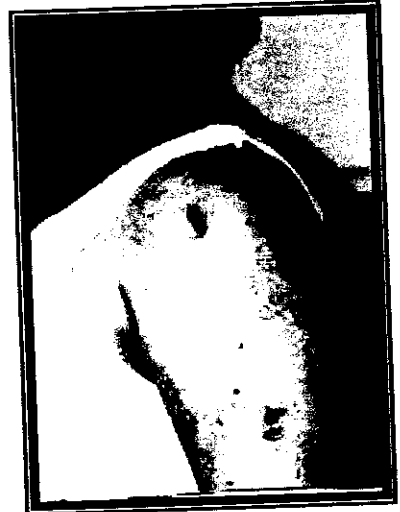Results



Results



Results



Results

Case number six :


58 years old , female, housewife, presented with right closed displaced Three-Part Proximal Humeral Fracture as a result of domestic injury .

She was operated upon after 48 hours of admission after a failed attempt of closed reduction and immobilization in U-shaped slab , as she needed to manage her uncontrolled diabetes mellitus , and discharged from the hospital after more 24 hours .

Post operative follow up three phase rehabilitation system was performed . During follow up period clinical and radiological assessment revealed the following last results :

- Fracture healing with radiological evidence of callus formation after 10 weeks post operatively and the fixator was removed after 12 weeks without remnant complications. (No X rays to show this ?
- She was subjected to the Neer's rating system and showed satisfactory result with overall score 86 .

Results



Results



15/11
Science



Results

Case number seven:

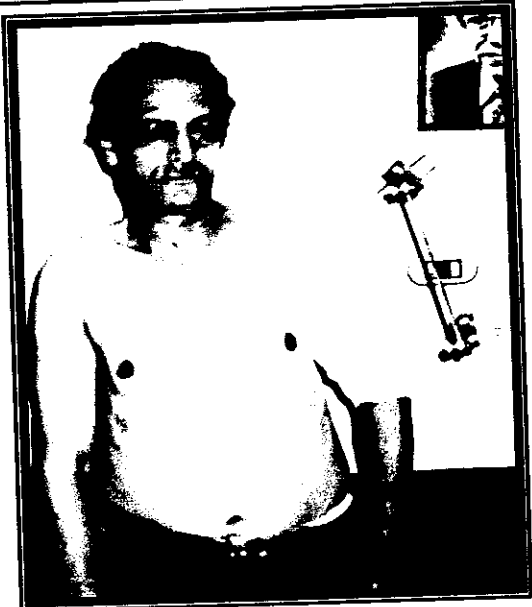
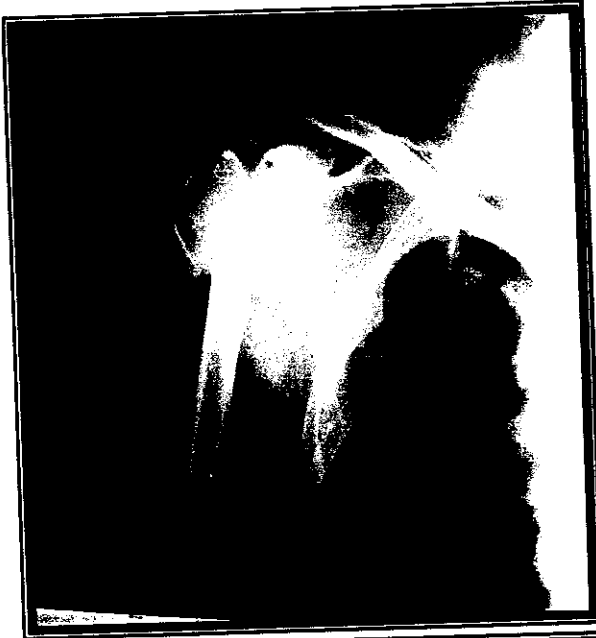


63 years , male , retired clerk , presented with left closed displaced Three-Part Proximal Humeral Fracture as a result of road traffic accident.

He was operated upon after 48 hours of admission , and discharged from the hospital after more 24 hours .

Post operative follow up three phase rehabilitation system was performed . During follow up period clinical and radiological assessment revealed the following last results :

- Fracture healing with radiological evidence of callus formation after 8 weeks post operatively and the fixator was removed after 8 weeks . → No Sw
o (halo)
- He was subjected to the Neer's rating system and showed satisfactory result with overall score 83 .

Results




Results



No radiologic
signs of
healing
of this fracture

Results



??

??

Results

Case number eight :

68 years old , female, housewife, presented with right closed displaced Three-Part Proximal Humeral Fracture with segmental comminution of the humeral shaft as a result of road traffic accident .

She was operated upon after 48 hours of admission , and discharged from the hospital after more one week to control her medical condition .

Post operative follow up three phase rehabilitation system was performed vigorously due to lack of patient's co-operation .

During follow up period clinical and radiological assessment revealed that there were no radiological evidence of callus formation after 16 weeks post operatively and thus she needed bone marrow injection in the fracture site under radiological control five months after injury and was clinically and radiologically assessed 6 weeks after bone marrow injection revealing radiological evidence of fracture healing.

- She was subjected to the Neer's rating system and showed unsatisfactory result with overall score 75 .